

## VARIANT ANATOMY OF THE EXTERNAL JUGULAR VEIN

Beda O. Olabu, Poonamjeet K. Loyal, Bethleen W. Matiko, Joseph M. Nderitu, Musa K. Misiani, Julius A. Ogeng'o

Corresponding Author: Beda Otieno Olabu P.O.Box 30197 – 00100 GPO, Nairobi Kenya  
Email: [bedaotn@yahoo.com](mailto:bedaotn@yahoo.com) or [otienobeda@gmail.com](mailto:otienobeda@gmail.com). Cell phone: +254 720 915 805 or +254 736 791 617

### ABSTRACT

Variant anatomy of the external jugular vein is important when performing invasive procedures in the neck. Although there are a number of case reports on some of these variations, there are few descriptive cross-sectional regarding the same. This study therefore aimed at describing the variant anatomy of the external jugular vein as seen in a sample Kenyan population. One hundred and six (106) sides of the neck from 53 cadaveric specimens (70 males and 36 females) in the Department of Human Anatomy, University of Nairobi, Kenya, were used. Pattern and level of formation, course, communications and termination were studied by dissection. The vein was absent in 14.2% of cases, all males. It was formed within the substance of the parotid gland in 44%, and did not receive posterior auricular vein in 6.6%. Variant communications noted included facial vein, internal jugular, and a presence of a large anastomotic vein connecting it to the anterior jugular. It was duplicated in 2.2% cases and terminated into internal jugular vein in 7.7% of cases. The most common variations were in origin, course, communications and termination. These may limit its clinical utilization, and their awareness is important when considering the vein for any invasive procedure. This may avoid unnecessary time wastage and complications of device malposition.

**Key Words:** External Jugular Vein; Variations; Communications; Absence; Termination

### INTRODUCTION

The external jugular vein (EJV) is usually formed by union of the posterior division of the retromandibular vein (RMV) with the posterior auricular vein near the mandibular angle just below or within the parotid gland (Gray's Anatomy). It terminates in the subclavian vein at the root of the neck after being joined by the posterior external jugular, transverse cervical, suprascapular and anterior jugular veins. Superficially located, the EJV represents a convenient venous conduit that can be easily and safely accessed during venous cutdown approach as a peripheral point of entry into the central venous system (Trerotola, 1997; Povoski, 2004; Cho et al., 2006; Povoski, 2007; Karaaslan et al., 2009). Cannulation of EJV has also been proved to be particularly useful in emergency setups such as infants and children in shock or severe dehydration (Haas, 2004)

and in cardiac arrest patients (Grevstad et al., 2009). The complex neurovascular anatomy in the neck requires precision with these procedures. Anatomic variations in this region therefore are not only important to anatomists, but pose an even greater, and often unforeseen, challenge to the clinicians including operating surgeon (Povoski, 2007; Reinhardt et al., 2011) and interventional radiologists who perform trans-jugular procedures (Nayak 2006; Vadgaonkar et al., 2008).

When compared with other vessels of the neck, fewer studies are present about the course and variations of the external jugular vein (Choudhry et al., 1997; Comert and Comert, 2009; Bergman et al., 2011). Reported variations are mainly case reports and include

absence (Bergman et al., 2011; Bertha and Suganthy, 2011), duplication (Bergman et al 2011; Comert and Comert, 2009), direct continuation of posterior auricular (Bergman et al), direct continuation of the RMV (Yadav et al., 2000; Bertha and Suganthy, 2011), receiving of common facial vein (Gupta et al., 2003; Bertha and Suganthy, 2011), coursing anterior to the clavicle (Bergman et al; Reinhardt et al., 2011) and abnormally lower

level of formation (Vollala et al., 2008). Prior knowledge of the existence of these variations may be important in before doing these procedures is necessary to avoid diagnostic pitfalls or avert therapeutic disasters (Johnson et al., 2009), and in understanding anatomy related complications. This study is aimed at describing the variations of the external jugular vein in a black Kenyan population.

## MATERIALS AND METHODS

One hundred and six (106) sides of the neck from 53 cadaveric specimens (70 males and 36 females) routinely used by first year medical students for dissection in the Department of Human Anatomy, University of Nairobi, were dissected to study the variant anatomy of the EJV. With the cadaver placed in the supine position, skin incisions were made in the midline of the neck and along the inferior border of the mandible and the skin flaps

reflected laterally. The platysma muscle was bilaterally removed from its proximal attachment and the EJV exposed. The vein was dissected to clearly show the formation, course, tributaries and termination. The level and mode of formation, course in relation to the sternocleidomastoid muscle, tributaries and pattern of termination and symmetry were noted.

## RESULTS

One hundred and six sides of the neck from 53 cadavers were dissected for the variant anatomy of the EJV. The vein was present in 91 cases (85.8%). All the 15 cases (14.2%) where the EJV was absent were noted from male cadavers, 9 on the right (60%) and 6 on the left sides of the body (40%), and was statistically significant ( $p$ -value = 0.54). Where the vein was absent, the posterior auricular vein was not traceable, and the whole retromandibular vein coursed anteroinferiorly to join the facial vein without dividing into anterior and posterior divisions (Figure 1).

Where present, the EJV was classically formed by the union of posterior auricular vein (PAV) with posterior division of retromandibular vein (RMV) in 75 cases (82.4%), direct continuation of the PAV in 10 cases (11.0%), and a direct

continuation of the retromandibular vein in 6 cases (6.6%). In one case, there was a hypoplastic EJV, and a large anterior division of RMV, which joined with both facial and lingual veins. The common trunk formed by these three drained both to the internal jugular vein and subclavian vein, with the presence of a large anastomosing vein running anterior to the sternocleidomastoid (Figure 2).

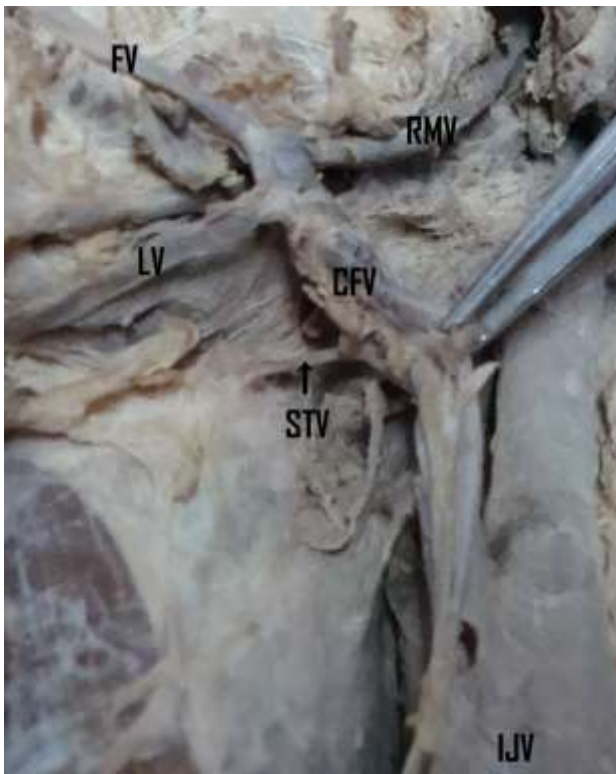
In the 75 cases where the EJV was formed by PAV and posterior division of RMV, four types were noted with regard to the level of confluence: (a) within parotid and behind mandibular angle [26 cases]; (b) within parotid but below mandibular angle [7 cases]; (c) below parotid but behind mandibular angle [2 cases]; and (d) below both parotid and mandibular angle [40 cases] {Table 1}.

**Table 1: Level of union of Retromandibular Vein and Posterior Auricular Vein to form the EJV**

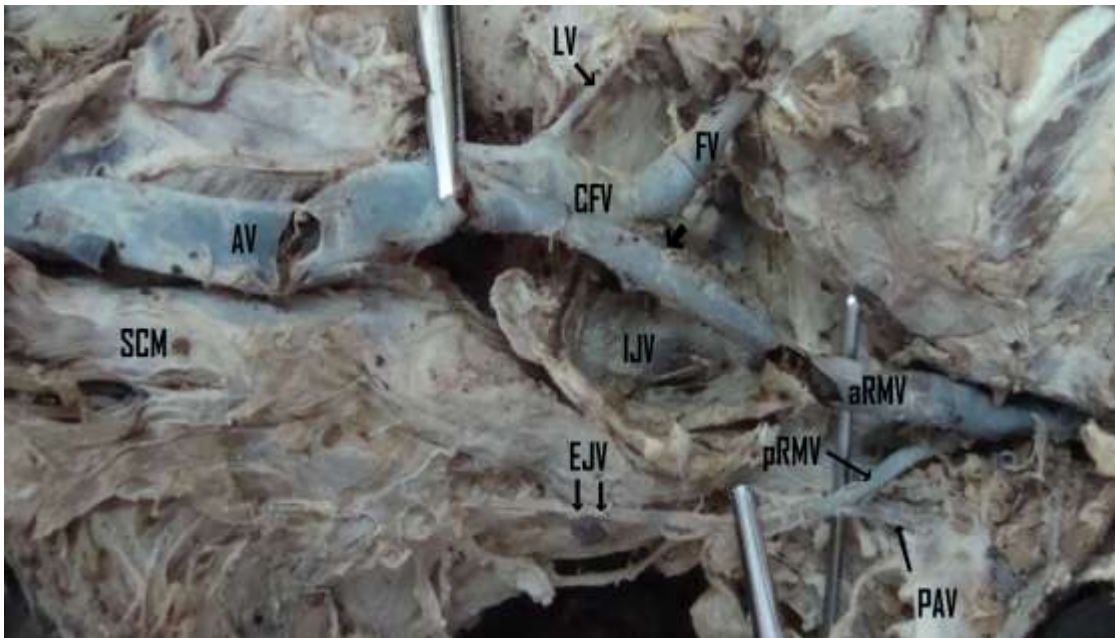
	Mandibular Angle		Total
	Behind	Below	
Within Parotid Gland	26 (34.7%)	7 (9.3%)	33 (44%)
Below Parotid Gland	2 (2.7%)	40 (53.3%)	42 (56%)
Total	28 (37.3%)	47 (62.7%)	75 (100%)

The EJV received the facial vein in 8 cases (8.8%). In all of these the EJV coursed along the anterior border of the sternocleidomastoid muscle, and either terminated in the subclavian


vein, internal jugular vein or the junction between the two except in one case where it terminated in both (Figure 3).



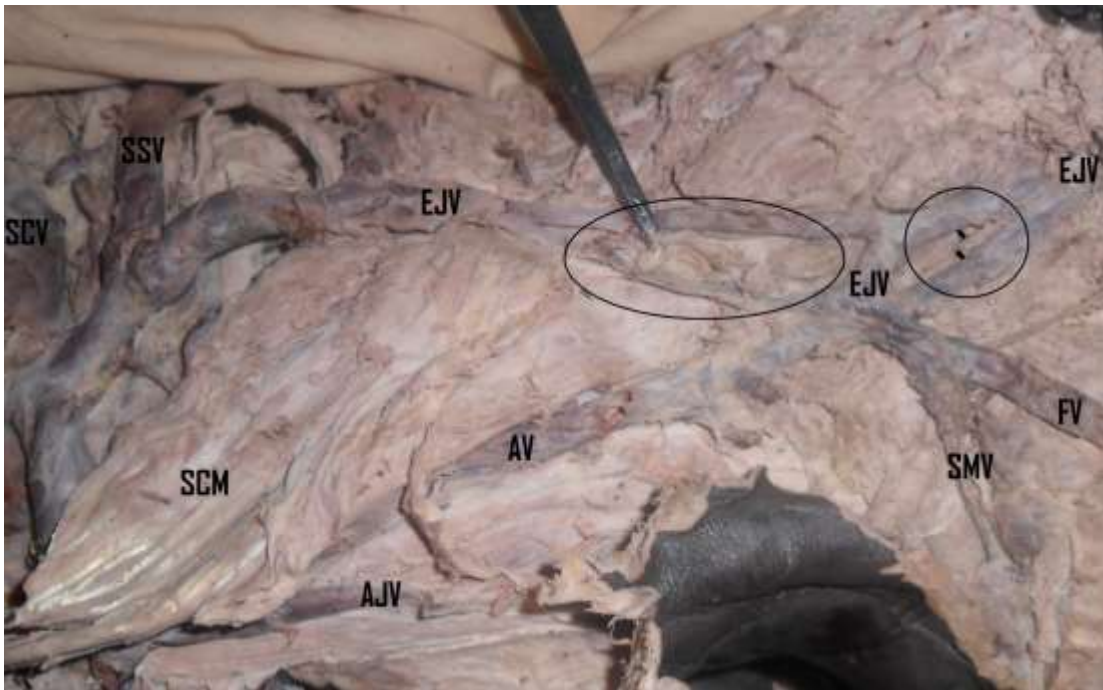
**Figure 1: Absent External Jugular Vein.** An absent External Jugular Vein. The whole Retromandibular Vein (RMV) joining Facial Vein to form the Common Facial Vein (CFV). The Lingual Vein (LV) and Superior thyroid Vein (STV) in this case also drained into the CMF, which eventually terminated into the Internal Jugular Vein (IJV).



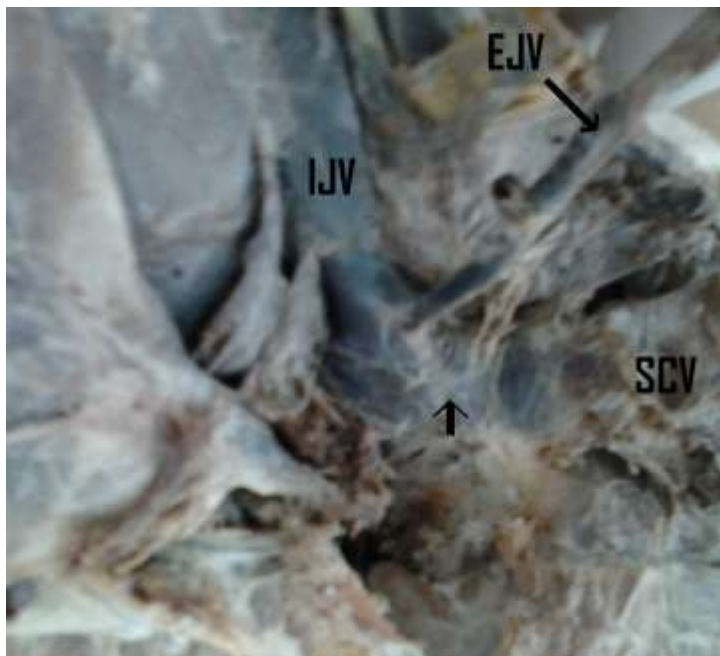
**Figure 2: Hypoplastic External Jugular Vein.** Hypoplastic External Jugular Vein (EJV), formed classically by the union of Posterior Auricular Vein (PAV) and posterior division of retromandibular Vein (pRMV). The Common Facial Vein (CFV), formed by anterior division of retromandibular Vein (aRMV) and Facial Vein (FV), drained both to the Internal Jugular Vein (IJV)[arrow head] and to the Subclavian Vein by a large anastomotic vein (AV) which coursed anterior to the Sternocleidomastoid Muscle (SCM).




**Figure 3: Facial Vein Joining the External jugular Vein.** Facial Vein (FV) joining External Jugular Vein. In this particular case, the EJV took a course anterior to the Sternocleidomastoid Muscle (SCM) but duplicated a few centimeters distally (arrowed), with one division draining into the Internal Jugular Vein (IJV) and the other joining the subclavian vein after receiving the Anterior Jugular Vein (AJV).



**Figure 4: Multiple duplication of the External Jugular Vein.** The External Jugular Vein (EJV) duplicating (smaller circle) then reunite. At this junction it is also joined by the Facial Vein (FV) after it has just received a Submental Vein (SMV). From the union with the FV an Anastomotic Vein (AV) is given that courses anterior to the sternocleidomastoid muscle (SCM) to join the Anterior Jugular Vein (AJV), and a second duplication is also noted (larger circle). The branches reunite again and terminate into the Subclavian Vein (SV) after receiving the Suprascapular Vein (SSV) and Transverse



**Figure 5: External Jugular Vein terminating into Internal Jugular Vein.** The External Jugular Vein (EJV) terminating into the Internal Jugular Vein (IJV), about 5mm proximal to the union (arrowed) with the Subclavian Vein (SV).



**Figure 6: External Jugular Vein running anterior to sternocleidomastoid then courses deep to it before termination.** External Jugular Vein (EJV) running along the anterior border of Sternocleidomastoid muscle (SCM) then courses deep to its sternal head before terminating into the Subclavian Vein (SV). In this case the Anterior Jugular Vein (AJV) joined the EJV just before it went deep to the muscle.

The EJV duplicated in two cases, one from the left and the other from the right side of the body in different individuals. In the first case the vein duplicated and the two branches terminated separately, one to subclavian vein and the other to internal jugular vein (Figures 3). In the second case the vein duplicated and joined, forming an ovoid ring, receiving facial vein near this junction, then reduplicated and rejoined again, forming a larger ring. From the junction with the facial vein the EJV sent a large anastomotic vein to the anterior jugular vein which coursed in front of the sternocleidomastoid muscle like in the cases where the EJV was after receiving a facial vein. This EJV eventually terminated in the

subclavian vein after receiving its other tributaries namely the suprascapular and transverse cervical veins (Figure 4).

The EJV terminated into the ipsilateral subclavian vein in 84 of cases (92.3%). In the other remaining cases, the vein either terminated into the internal jugular vein (5 cases; 5.5% - Figure 5), or at the junction between the internal jugular vein and the subclavian vein (2 cases; 2.2%). An EJV running anterior to the sternocleidomastoid muscle coursed either superficial (4 cases) or deep (4 cases) to the muscle before termination (Figure 6).

## DISCUSSION

The EJV showed variations in presence, formation, level of formation, course,

communications and termination, concurring with literature reports that the vein is so

variable that it is hard to define its “normal pattern”(Bergman et al 2011). These anomalous patterns may partly be explained by embryological occurrence of unusual retention and/or regression of venous anastomotic channels in the primitive pharyngeal region during development (Bertha and Suganthy, 2011).

### **Absence and Hypoplasia of the EJV**

The EJV was absent in 14.2% of the cases, all from male cadavers and majority from the right side of the body. Although the absence of the EJV has been reported in literature (Cunningham, Bergman et al 2011), the incidence of this is markedly lacking, most studies only reporting it as cases. A study done in American Whites and Negroes reported 3.5%, mostly from the whites than the blacks, and all were from male cadavers (Brown, 1941). Although the case reports specified neither sex nor side of the body (Bertha and Suganthy, 2011), based on our observations and the reports of Brown (1941), it is probable that this variation occurs significantly in males than in females. A hypoplastic EJV which was noted in one of our cases may be considered an intermediate stage towards absence of the vein. A small EJV is however known to be associated large internal jugular or anterior jugular veins (Cunningham, Stickle and McFarlane, 1997). This concurs with the observations of the present study, where the anterior jugular vein was noted to be large, with the presence of a large anastomotic vein. We did not however study the diameters of anterior and internal jugular veins in relation to the occurrence or size of the EJV.

It has been suggested that there is an inverse correlation between EJV and IJV diameters (Stickle and McFarlane, 1997). This relationship is known to be important in occlusions of the right IJV, in which the right EJV is enlarged, hence, can be used as an alternative site for central catheterization (Cho et al., 2006). Since

the EJV may be absent in about one out of ten individuals, this should be borne in mind when attempting surgical procedures on the vein, and unnecessary time should not be spent in looking for it during emergency situations if the vein cannot be easily recognized. Nevertheless, although an absent or hypoplastic EJV may not favor its clinical utilization, it is possible that under these circumstances the anterior or internal jugular veins may be large enough to favor clinical procedures that were initially intended for the EJV, other factors kept constant.

### **Mode and Level of Formation**

The union of posterior auricular vein and the posterior division of the RMV classically form the EJV, and this was confirmed by our current findings in the majority of cases (82.4%). Although there is scarcity of data on patterns of EJV formation, this mode was also noted by Brown (1941) to be the most common type, but the incidence was much lower than in our situation (34.1%). Direct continuation from either posterior auricular or retromandibular veins which were noted in our study have also been reported by other authors, but mostly as case reports (Brown, 1941; Nayak and Soumya, 2008; Vadgaonkar et al., 2008; Choudhary et al., 2010). The direct continuation from the retromandibular vein did not seem to affect the size of the EJV, perhaps because the usual contribution from the posterior auricular is not a large. Since the retromandibular vein is used as a guide to expose the facial nerve branches in superficial parotidectomy and in open reduction of mandibular condylar fractures (Choudhary et al., 2010), it may pose confusion during surgical procedures when it is undivided and just continuing into EJV. Another challenge may also arise where the EJV is formed within the substance of the parotid gland as it were in 44% of our cases, where these veins may provide a surgical dilemma during these operations.

### **Unusual Course and Communications**

Other than the usual known tributaries of the EJV, the facial vein was noted to provide the most common unusual communication with the EJV (8.8%). This type of communication is fairly common and has been reported by other workers, with varying incidences as shown in Table 2. This may represent a persistent communication of the primitive linguofacial vein with the secondarily developing EJV, anastomotic channel that is usually present for some time in the fetus but later undergoes retrogression (Choudhry et al., 1997).

The next common communication was that with other jugular veins. The communication with the anterior jugular vein is known to be fairly common, but the presence of a large anastomotic vein observed in the present study is scarcely reported. This anastomotic vein was noted to be large when the EJV was either hypoplastic or receiving facial vein, or in a background of a complex venous variation in the neck. During cannulation and catheterization, an EJV approach does not necessitate surgical cut-down for venous

access, avoids deep vascular punctures in the neck and groin, and is safe in patients with coagulopathy (McCowan et al., 1990). However, although may be significantly enlarged, an anastomotic vein, together with an EJV that courses anterior to the sternocleidomastoid may not favor these “blind” clinical procedures due to their unstraight course and perhaps other possibly associated venous malformations which may be unforeseen. Other reported communications but which were not observed in the current study include cephalic vein contribution at the upper border of the clavicle (Kim and Han, 2010).

### Duplication and Termination

The termination of the EJV was predominantly into the ipsilateral subclavian vein as expected. However in about one out of twenty the vein may end in the IJV, or the junction between SV and IJV in 2% of situations. Other authors have also documented anomalous termination of the EJV into the IJV (Shailaja et al., 2006) and at the junction of IJV and SV (Kim and Han, 2010) in

**Table 2: Prevalence of communication between facial vein and EJV**

Author	Population	Sample	Incidence
Brown, 1941	America	179	8.4%
Choudhry et al., 1997	India	80	5%
Bertha and Suganthy, 2011	India	35	8.6%
Nayak et al., 2008	India	Case report	-
Vadgaonkar et al., 2008	India	Case report	-
Choudhary et al., 2010	India	Case report	-

case reports. As noted in the present study, in the presence of duplication the EJV may

terminate in more than one vein. These duplications, also noted by other authors.



In conclusion, the EJV displays a wide variation in occurrence, level and mode of formation, size, course, communications and termination. Although the vein is fairly superficial, this

variant anatomy may not favor “blind” surgical procedures in the neck. When not fairly visible, we do not recommend extra time spent looking for the vein, especially in emergency situations.

## REFERENCES

1. Bergman RA, Afifi AK, Miyauchi R. Illustrated encyclopedia of human anatomic variation: Opus II: Cardiovascular system: Veins: Head, neck, and thorax. <http://www.anatomyatlases.org/AnatomicVariants/Cardiovascular/Text/Veins/JugularExternal.shtml>. Accessed on April 18, 2011.
2. Bertha A, Suganthy R. Anatomical Variations in Termination of Common Facial Vein. *Journal of Clinical and Diagnostic Research* 2011; 5(1):24-27.
3. Brown S. The external Jugular vein in American Whites and Negroes. *American Journal of Physical Anthropology* 1941; 28(2):213-226.
4. Cho SK, Shin SW, Do YS, Park KB, Choo SW, Choo IW. Use of the right external jugular vein as the preferred access site when the right internal jugular vein is not usable. *J Vasc Interv Radiol* 2006; 17(5):823-829.
5. Choudhary S, Sharma AK, Singh H. Undivided Retromandibular Vein Continuing As External Jugular Vein With Facial Vein Draining Into It: An Anatomical Variation. *JK Science* 2010; 12(4):203 – 204.
6. Choudhry R, Tuli A, Choudhry S. Facial vein terminating in the external jugular vein. An embryologic interpretation. *Surg Radiol Anat.* 1997; 19(2):73-77.
7. Comert E, Comert A. External jugular vein duplication. *J Craniofac Surg* 2009; 20(6):2173-2174.
8. Cunningham DJ. *The Vascular System: Abnormalities of Veins* pg 1058.
9. Grevstad U, Gregersen P, Rasmussen LS. Intravenous access in the emergency patient. *Current Anaesthesia & Critical Care* 2009; 20: 120–127.
10. Gupta V, Tuli A, Choudhry R, Agarwal S, Mangal A. Facial vein draining into external jugular vein in humans: its variations, phylogenetic retention and clinical relevance. *Surg Radiol Anat* 2003; 25(1): 36-41.
11. Haas NA. Clinical Review: Vascular access for fluid infusion in children. *Critical Care* 2004; 8:478-484.
12. Johnson MH, Thorisson HM, Diluna ML. Vascular anatomy: the head, neck, and skull base. *Neurosurg Clin N Am.* 2009; 20(3):239-258.
13. Karaaslan D, Altinisik U, Peker TT, Nayir E, Ozmen S. External Jugular Vein Catheterization Using 'Intra-Atrial Electrocardiogram'. *Yonsei Med J* 2009; 50(2):222-226.
14. Kim DI, Han SH. Venous variations in the Neck Region: Cephalic Vein. *International Journal of Anatomical Variations* 2010; 3: 208–210.
15. Lalwani R, Rana KK, Das S, Khan RQ. Communication of the External and Internal Jugular Veins: A Case Report. *Int. J. Morphol* 2006; 24(4):721-722.
16. McCowan TC, Ferris EJ, Carver DK, Harshfield DL. Use of external jugular vein as a route for percutaneous inferior vena caval filter placement. *Radiology* 1990; 176:527-530.
17. Nayak BS, Soumya KV. Abnormal formation and communication of external jugular vein. *International Journal of Anatomical Variations* 2008; 1: 15–16.
18. Nayak BS. Surgically important variations of the jugular veins. *Clin Anat.* 2006; 19(6):544-546.

19. Povoski SP. Eliminating the "Pitfalls" of chronic indwelling central venous access device placement in cancer patients by utilizing a venous cutdown approach and by selectively and appropriately utilizing intraoperative venography. *International Seminars in Surgical Oncology* 2007; 4:16.
20. Povoski SP: The external jugular vein cutdown approach for central venous access in cancer patients: A potentially useful alternative. *World J Surg Oncol* 2004, 2:7.
21. Reinhardt KR, Kim HJ, Lorich DG. Anomalous external jugular vein: clinical concerns in treating clavicle fractures. *Arch Orthop Trauma Surg* 2011; 131(1):1-4.
22. Shailaja C.Math, K.Sandhya, G.B. Rairam. Variation in the Termination of External Jugular Vein – A Case Report: *Journal of the Anatomical Society of India* 2006; 55 (1):
23. Stickle BR, McFarlane H. Prediction of a small internal jugular vein by external jugular vein diameter. *Anaesthesia* 1997; 52: 220-222.
24. Trerotola SO. You are asked to place a dialysis access catheter in a patient. What is your preferred access site, and why? *J Vasc Interv Radiol* 1997; 8:75-76.
25. Vadgaonkar R, Rai R, Ranade AV, Pai MM, Prabhu LV, Ashwin K, Jiji PJ. An anomalous left external jugular vein draining into right subclavian vein. *Bratisl Lek Listy*. 2008; 109(10):461-462.
26. Vollala VR, Bolla SR, Pamidi N. Important vascular anomalies of face and neck – a cadaveric study with clinical implications. *Firat Tip Dergisi*. 2008; 13; 123–126.
27. Yadav S, Ghosh SK, Anand C. Variations of superficial veins of head and neck. *J. Anat. Soc. India*. 2000: 49; 61–62.