



Intima – Media Thickness of Left Anterior Descending Coronary Artery in a Black Kenyan Population: Correlation with Morphological Features

Julius A Ogeng'o, Justus P Kilonzi, Phillip M Mwachaka, Nafula M Ogeng'o, Musa K Misiani* and Acleus Murunga

Department of Human Anatomy, University of Nairobi, P.O. BOX 30197 – 00100 Nairobi, Kenya

*Corresponding author: Musa Kerobu Misiani, Department of Human Anatomy, University of Nairobi, PO BOX 30197–00100 Nairobi, Kenya, Tel: 254-726420377; E-mail: jogengo@uonbi.ac.ke

Rec Date: Jul 10, 2014; Acc Date: Nov 12, 2014; Pub Date: Nov 20, 2014

Copyright: © 2014 Ogeng'o, et al. This is an open-access article distributed under the terms of the Creative Commons Attribution License, which permits unrestricted use, distribution, and reproduction in any medium, provided the original author and source are credited.

Abstract

Background: Intima-Media thickness is an acknowledged surrogate marker for predicting and profiling of atherosclerotic cardiovascular disease. It displays geographical and ethnic variation but is seldom reported among black populations of Africa. The left anterior descending coronary artery is one of the most frequently afflicted arteries by atherosclerosis. This study, therefore, aimed at correlating its intima – media thickness with morphological features of left coronary artery in a black Kenyan population.

Materials and methods: Materials for this study were 126 hearts obtained during autopsy at the Department of Human Anatomy, University of Nairobi Kenya from black adult Kenyans [72 males, 54 females] who died of non-cardiovascular causes. The left coronary artery was identified, its termination pattern recorded and its length and bifurcation angle measured. Specimens for light microscopy were taken from the proximal segment of the left anterior descending artery and processed for paraffin embedding and sectioning. Five micron sections were stained with Masson's trichrome and examined at magnification x35. The results were analyzed using SPSS version 17.0. Student t-test was performed at 95% confidence interval where $p < 0.05$ was taken to be statistically significant. They are presented in micrographs and tables.

Results: The mean intima – media thickness was 0.332 mm. It was higher in males (0.357 ± 0.06 mm) than in females (0.25 ± 0.03 mm), increased with number of branches of left coronary artery, from 0.336 ± 0.014 mm in bifurcation to 0.506 ± 0.01 mm in pentafurcation; and was also higher in left coronary arteries that were shorter than 5 mm and those with bifurcation angles $>80^\circ$.

Conclusion: The intima – media thickness of left anterior descending artery is influenced by length, bifurcation angle and terminal branching pattern of left coronary artery, and is higher in males than in females. This suggests that these morphological features of left coronary artery constitute anatomical risk factors for atherosclerosis. Individuals with these features should be screened for atherosclerosis, to inform early intervention.

Keywords: Intima–Media Thickness; Length; Bifurcation angle; Branching pattern; Coronary artery

Materials and Methods

Introduction

Intima–Media Thickness (IMT) is a reliable sensitive marker of subclinical atherosclerosis [1-3] and an independent predictor of cardiovascular events and target organ damage [3,4]. It is also valuable in evaluation and stratification of cardiovascular disease risk, prediction of long term outcome and monitoring ongoing disease progression and regression [1,2,5]. Atherosclerotic diseases are increasing in Sub Saharan Africa including in Kenya [6,7]. Data on IMT from black African populations, however, though important in mitigating further rise in prevalence of the disease, remain scarce. Left anterior descending (LAD) artery is the most commonly afflicted of the coronary arteries. Recent studies reveal that features of atherosclerosis are present in this artery from an early age [8,9]. This study therefore aimed at correlating IMT in this artery with morphological features of left coronary artery (LCA) among black Kenyans.

This study was done on autopsy material from samples of 126 victims (72 males; 54 females) of trauma in whom there was no record of cardiovascular disease. Those who were aged below 18 or over 55 years, who died of cardiovascular disease such as hypertension, myocardial infarction, stroke, diabetes, renal disease and peripheral vascular disease, were excluded. Only those in whom the cause of death was purely traumatic were included. The main causes of trauma were road traffic accident (47.6%); gunshot wounds (35.7%); burns (11.9%) and electrocution (4.8%). Those in whom there was a history of tobacco smoking, alcohol drinking, HIV and other viral and bacterial infections were also excluded. The age range was 21 – 53 years. [Mean 43.5 ± 5.0 years]. Seventy one (56.3%) were aged below 40 years with only 7 (5.6%) being over 50 years. The chest cavity was opened, and pericardium incised longitudinally to expose the heart, which was harvested by diving it from the great vessels 2 cm from its base. The hearts were weighed using a Settler TM balance to the nearest gram. Size of the heart was measured at the point of maximum width, using a pair of dividers. The LCA and LAD were exposed by dissection. Hearts weighing more than 450 grams were excluded. 2 mm long specimens were taken from the proximal LAD and processed

for light microscopy. Specimens were taken within 72 hours of death, to avoid those with overt postmortem damage to the tissues. They were fixed by immersion in 10% formaldehyde solution for three days, then trimmed and processed routinely for paraffin embedding by passing them through increasing concentrations of isopropyl alcohol, (50%; 60%; 70%; 80%; 90%; 95% and 100%) each for one hour and cleared with cedar wood oil for 12 hours. The sections were then infiltrated with fresh molten paraplast wax for 12 hours, and embedded in wax. Five micrometer sections were stained with Masson's trichrome.

Morphometry was done on light microscopy slides. Ten serial sections from each specimen were used. Analogue photographs were taken using a photomicroscope at a constant magnification of X35. The photographs were then scanned using a HPTM scanner and analyzed using Scion Image TM Multiscan software. Intimal and medial thickness was measured. The extent of the intima was defined as between the lumen and the internal elastic lamina. Four random points (ISa, ISb, ISc, ISd) were selected and the average was computed based on the protocol by [10]. The media was defined as the area between the internal elastic lamina and the external elastic lamina. Four random points (Msa, Msb, Msc, Msd) (Figure 1) were selected and the average size computed.

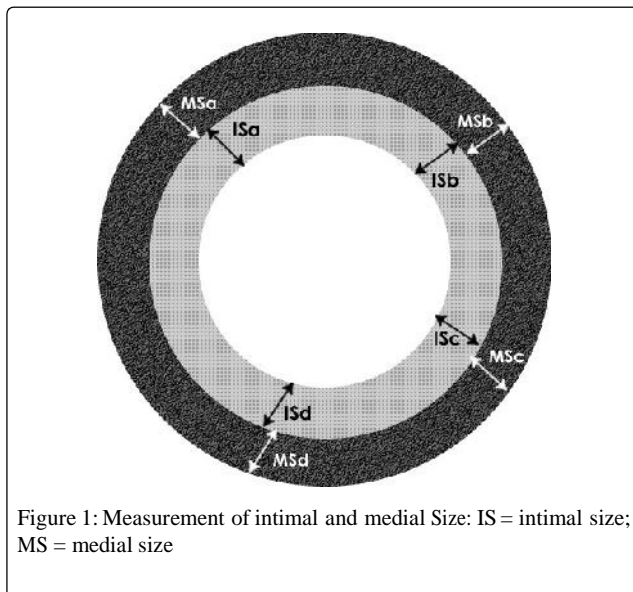


Figure 1: Measurement of intimal and medial Size: IS = intimal size; MS = medial size

Data gathered were coded, tabulated and analyzed using the Statistical Program for Social Sciences (SPSS) for Windows TM version 17.0. Descriptive statistics were applied to determine means, frequencies and ranges for intimal and medial thickness. The Intima – Media Thickness was taken to be the sum of the thickness of the intima and that of the media. Intima – media thickness was corrected for heart weight and size. Student t – test was used, at 95% confidence interval where the differences were considered significant at $p < 0.05$. The results are presented by means of micrographs and tables.

Results

Mean IMT was 0.332 ± 0.06 mm. It was predominantly due to tunica media in mild hyperplasia (Figure 2A), which was present in nearly 50%. In over 30% of the cases, IMT was due to intimal thickness which contributed over 50% (Figure 2B), in some cases forming over

80% (Figure 2C). In 50% of the cases, high IMT was associated with thick highly vascularized tunica adventitia (Figure 2D).

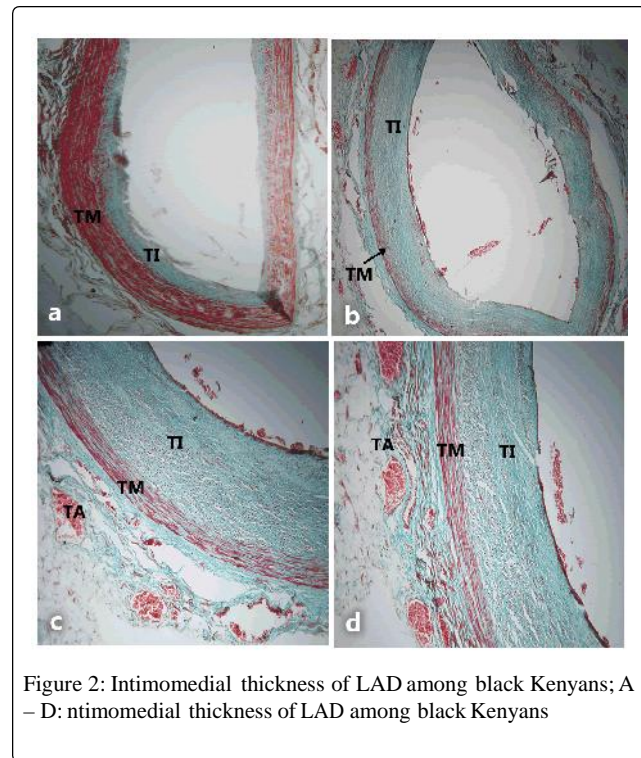


Figure 2: Intimomedial thickness of LAD among black Kenyans; A – D: ntimomedial thickness of LAD among black Kenyans

Mason's Trichrome stain x 100. TI = Tunica Intima; TM = Tunica Media; TA = Tunica Adventitia.

A: Full wall thickness of LAD in a 35 year old male showing IMT predominantly formed of TM. Note the thin TI forming only 20 – 30% of IMT;

B: TI and TM of LAD in a 43 year old male showing predominance of tunica intima contributing over 50% of the IMT.

C: TI and TM of LAD in a 51 year old female showing the overt predominance of tunica intima which contributes nearly 80% of IMT;

D: Full wall thickness of LAD in a 48 year old male showing thickened (TA) forming almost 50% of the wall thickness. Note thick highly vascularized tunica adventitia.

IMT was higher in males (0.357 ± 0.06 mm) than in females (0.25 ± 0.03 mm). This difference was statistically significant [$p=0.01$] and persisted even after correcting for heart size and weight. Differences between age groups were not statistically significant and disappeared after correcting for heart weight. The intima - media thickness was correlated with branching pattern, length and bifurcation angle of left coronary artery.

The branching pattern of LCA comprised bifurcation (54.8%), trifurcation (32.3%), quadrifurcation (9.7%) and pentafurcation (3.2%). The IMT increased from 0.336 ± 0.01 in bifurcation to 0.506 ± 0.01 mm in pentafurcation. This difference was statistically significant ($p=0.001$). The sex difference for bifurcation and trifurcation was statistically significant. There were no female cases with either quadrifurcation or pentafurcation (Table 1).

Branching Pattern of LCA	IMT of LAD (mm)	p value
	Mean ± SE	
Bifurcation	Overall 0.336 ± 0.014	0.015
	Male 0.337 ± 0.02	
	Female 0.302 ± 0.016	
Trifurcation	Overall 0.416 ± 0.02	0.02
	Male 0.418 ± 0.016	
	Female 0.88 ± 0.024	
Quadrifurcation	0.454 ± 0.014	N/A
Pentrafurcation	0.506 ± 0.01	N/A

Table 1: Mean IMT of LAD correlated with branching pattern of LCA

The mean length of LCA was 8.45 ± 0.52 mm (Range 2.0-18.5 mm). The majority (54.7%) were between 5 – 15 mm long. Sixteen (38.1%) measured 5 mm long while 3 (7.2%) measured 15 mm long. The IMT was inversely proportional to the length. It was highest (0.40 ± 0.03 mm) in the shortest and lowest (0.30 ± 0.012 mm) in the longer arteries (Table 2).

Length (mm)	Frequency	(%)	IMT (Mean ±SE)
0 – 2.5	21	-16.7	0.40 ± 0.03
2.6 – 5.0	27	-21.4	0.38 ± 0.01
5.1 – 7.5	30	-23.8	0.37 ± 0.02
7.6 – 10.0	18	-14.3	0.36 ± 0.001
10.1 – 12.5	12	-9.5	0.34 ± 0.002
12.6 – 15.0	9	-7.1	0.33 ± 0.001
15.1 – 17.5	3	-2.4	0.33 ± 0.001
17.6 – 20.0	6	-4.8	0.30 ± 0.012
Total	126	100	

Table 2: Correlation of length of LCA with IMT of LAD in a black Kenyan population

The mean angle of bifurcation was 61.9° ± 5.04 (Range 26-110°). Sixteen (38.1%) were between 61 - 80°. Eighteen (42.9%) were above 80°. Of these, 13 (31%) had a main trunk length of 5 mm. Only 8 (19.4%) were less than 60°.

The mean IMT increased with bifurcation angle such that it was 0.35 mm for those below 800 and 0.495 ± 0.02 mm for those above 800. The difference was significant (p = 0.025) (Table 3).

Angle (°)	Frequency	(%)	IMT (mm) Mean ± SD
26 – 40	7	-7.1	0.35 ± 0.02
41 – 60	15	-11.9	0.36 ± 0.01
61 – 80	48	-38.1	0.39 ± 0.03

81 – 100	30	-23.8	0.48 ± 0.02
>100	24	-19.1	0.50 ± 0.001
Total	126	100	

Table 3: Correlation of bifurcation angle of left coronary artery with IMT of LAD in black Kenyans

Discussion

Normal intimal thickness of LAD ranges from 100-350µm and medial thickness from 150-250 µm [11,12]. Intima – media thickness of 0.332 mm observed in the current study, is within the range reported in literature [13,14]. The age dependent increase is also concordant with literature reports [15]. This implies that predisposition to atherosclerosis associated with intima –media thickness is similar across populations, suggesting that the Kenyan population is as vulnerable to atherosclerosis as others.

The intima –media thickness was significantly higher in short coronary arteries than in normal and longer ones. This observation is consistent with literature reports that shorter common trunks of LCA are more prone to atherosclerosis [16-18].

It implies that in the Kenyan population, 37.1% of individuals may bear this intrinsic factor for atherosclerosis. Intima – media thickness was also higher in the arteries with variant branching pattern; that is trifurcation, quadrifurcation and pentafurcation. This is consistent with reports that unusual branching patterns cause disturbed flow, reducing wall shear stress, thus making the affected vessels more prone to atherosclerosis [19-21]. In this regard, 45.2% of the Kenyan population would be intrinsically, due to this structural determinant, prone to atherosclerosis. Another consistent anatomical feature associated with high IMT is the wide branching angle (>800). This is also consistent with literature reports that high bifurcation angles are associated with higher risk of atherosclerosis [22]. In the current study, 42.9% of the individuals had bifurcation angles >800; suggesting higher propensity to atherosclerosis. Accordingly, individuals who present for cardiovascular evaluation should be screened for termination pattern, bifurcation angle and length of LCA so that control measures for CVD may be commenced early.

High intima – media thickness causes coronary artery stenosis. Such stenosis and potential acute coronary syndromes correlate with carotid intima – media thickness, carotid plaque histology and cerebrovascular events [23,24]. Indeed, coronary atherosclerosis is associated with carotid atherosclerosis [25]. Accordingly, concurrent ultrasound screening of the vulnerable Kenyan population for carotid IMT may improve early detection of adverse cardiovascular risk.

Limitations

The main limitations of this study were the small sample size and the use of light microscopy to study postmortem specimens. Postmortem damage and tissue shrinkage during processing may undermine the results. Since all specimens were subjected to the same methodology, these would be errors of analysis carried through all the measurements hence the comparisons are still valid.

Conclusion

The intima – media thickness of left anterior descending artery is influenced by length, bifurcation angle and terminal branching pattern of left coronary artery, and is higher in males than in females. This suggests that these morphological features of left coronary artery constitute anatomical risk factors for atherosclerosis. Individuals with these features should be screened for atherosclerosis, to inform early intervention.

Acknowledgement

We are grateful to Jacob Gimongo, Margaret Irungu for technical support and Antonina Odock – Opiko for typing this manuscript.

References

1. Uthoff H, Staub D, Meyerhans A, Hochuli M, Bundi B, et al. (2008) Intima-media thickness and carotid resistive index: progression over 6 years and predictive value for cardiovascular events. *Ultraschall Med* 29: 604-610.
2. O'Leary DH, Bots ML (2010) Imaging of atherosclerosis: carotid intima-media thickness. *Eur Heart J* 31: 1682-1689.
3. Cobble M, Bale B (2010) Carotid intima-media thickness: knowledge and
4. Lorenz MW, Markus HS, Bots ML, Rosvall M, Sitzer M (2007) Prediction of clinical cardiovascular events with carotid intima-media thickness: a systematic review and meta-analysis. *Circulation* 115: 459-467.
5. Van Tits LJ, Smilde TJ, Van Wissen S, de Gracif J, Kastelein JJ, et al (2004) Effects of atorvastatin and simvastatin on low density lipoprotein subfraction profile, low density lipoprotein oxidizability and antibodies. To oxidized low density lipoprotein in relation to carotid intima media thickness in familial hypercholesterolemia. *J Invest Med*, 52: 177-184.
6. Mensah GA (2008) Ischaemic heart disease in Africa. *Heart* 94: 836-843.
7. Ogeng'o JA, Gatonga P, Olabu BO, Ongeti KW, Obimbo MM (2013) Pattern of atherosclerotic Diseases among Kenyans. Reality of myocardial Infarction. *MEDICOM: The Afr J Hosp Sci Med*; 28(2): 47-50.
8. Ogeng'o JA; Kilonzi J; Saidi H; Hassanali J (2010) Histomorphometric evidence of early onset coronary artery disease among Kenyans. *MEDICOM. The Afr J Hosp Med*; 19 – 24: 11 – 14.
9. Ogeng'o J, Ongeti K, Obimbo M, Olabu B, Mwachaka P (2014) Features of atherosclerosis in the tunica adventitia of coronary and carotid arteries in a black kenyan population. *Anat Res Int* 2014: 456741.
10. Nakashima Y, Chen YX, Kinukawa N, Sueishi K (2002) Distributions of diffuse intimal thickening in human arteries: preferential expression in atherosclerosis-prone arteries from an early age. *Virchows Arch* 441: 279-288.
11. Tuzcu EM, Kapadia SR, Tutar E, Ziada KM, Hobbs RE, et al. (2001) High Prevalence of coronary atherosclerosis in Asymptomatic Teenagers and Young Adults. Evidence from intravascular Ultrasound. *Circulation*, 103: 2705 – 2710.
12. Ullah QW, Qamar K, Butt SA. Wall thickness of major coronary arteries in Pakistani population. *Pak Armed Forces J*.
13. Yoshitani H, Takeuchi M, Ogawa K, Othuji Y (2009) Comparison of usefulness of the wall thickness of the left anterior descending coronary artery determined by transthoracic echocardiography, and carotid intima – media thickness in predicting multilevel coronary artery disease. *J Echocardiogr*, 7: 2 – 8.
14. Levy AD, Harcke HT, Mallak CT (2010) Postmortem imaging: MDCT features of postmortem change and decomposition. *Am J Forensic Med Pathol* 31: 12-17.
15. Velican D, Velican C (1980) Atherosclerotic involvement of the coronary arteries of adolescents and young adults. *Atherosclerosis* 36: 449-460.
16. Gazetopoulos N, Ioannidis PJ, Karydis C, Lolas C, Kiriakou K, et al. (1976) Short left coronary artery trunk as a risk factor in the development of coronary atherosclerosis. *Pathological study. Br Heart J* 38: 1160-1165.
17. Gazetopoulos N, Ioannidis PJ, Marselos A, Kelekis D, Lolas C, et al. (1976) Length of main left coronary artery in relation to atherosclerosis of its branches. A coronary arteriographic study. *Br Heart J* 38: 180-185.
18. Candir N, Ozan H, Kocabiyyik N, Kusakligil H (2010) Anatomic risk factors in coronary heart disease. *Trakya Univ Tip Fak Derg* 27:248:252.
19. Drug-eluting stent implantation in coronary trifurcation lesions. *J Invasive Cardiol* 19: 157-162.
20. Moore JE Jr, Timmins LH, Ladisa JF Jr (2010) Coronary artery bifurcation biomechanics and implications for interventional strategies. *Catheter Cardiovasc Interv* 76: 836-843.
21. Rubinstein R, Lerman A, Spoon DB, Rihal CS (2012) Anatomic features of the left main coronary artery and factors associated with its bifurcation angle: A 3-Dimensional quantitative coronary angiographic study. *Cath Cardiovasc Interv*, 80:304-309.
22. Sun Z, Cao Y (2011) Multislice CT angiography assessment of left coronary artery: correlation between bifurcation angle and dimensions and development of coronary artery disease. *Eur J Radiol* 79: e90-95.
23. Ciccone MM, Niccoli-Asabella A, Scicchitano P, Gesualdo M, Notaristefano A, et al. (2011) Cardiovascular risk evaluation and prevalence of silent myocardial ischemia in subjects with asymptomatic carotid artery disease. *Vasc Health Risk Manag* 7: 129-134.
24. Ciccone MM, Marzullo A, Mizio D, Angiletta D, Cortese F, et al. (2011) Can carotid plaque histology selectively predict the risk of an acute coronary syndrome? *Int Heart J* 52: 72-77.
25. Ciccone MM, Scicchitano P, Zito A, Agati L, Gesualdo M, et al. (2011c) Correlation between coronary artery disease severity, left ventricular mass index and carotid intima – media thickness, assessed by radio frequency. *Cardiovasc Ultrasound* 9: 32.